

The Neoss ProActive Edge implant.

Preliminary clinical experiences and results

Matteo Turra^{1,2}, Peter Andersson^{1,2}, Damiano Verrocchi², Lars Sennerby¹

¹ Clinica Feltre, Feltre, Italy

² Private practice, Fiera di Primiero, Italy

This retrospective chart study reports on the preliminary experiences with the clinical use of the novel Neoss Edge implant with regard to surgical handling, primary stability, and implant survival. Implant placement was found to be easy and gave a sensation of firm stability as also confirmed with ISQ measurements. One of 56 implants was lost and there were no indications of adverse marginal bone loss.

INTRODUCTION

Dental implant procedures should be safe, swift, and predictable to give patients the best possible treatment when replacing missing teeth. From a surgical point of view, it is desirable to use simple drilling protocols and an implant design that can reach good primary stability and integrate in all bone densities. A novel implant with features such as marked tapering, high thread pitch and wide and sharp threads has recently been developed.¹ This implant design, the Neoss Edge implant, is intended to speed up and simplify the surgical placement as only one or two drills are needed according to the manufacturer. The Neoss Edge implant was found to be effective in an in vitro study and showed comparable or higher primary stability than two commercially available implants with similar geometry as assessed by insertion torque (IT), Implant Stability Quotient (ISQ) and displacement measurements.² A recent clinical case series study reported that 13 of 25 Edge implants could be placed after the use of one spiral drill only.¹ Moreover, the implants reached high stability also in maxillary bone, where most implants had been used.

The aim of the study was to retrospectively evaluate the primary stability and clinical performance of 54 Neoss Edge implants in 36 consecutive patients after up to 3 years in function.

MATERIALS & METHODS

This retrospective case series study comprised of consecutive routine patients missing one or several teeth and previously treated with a novel dental implant (ProActive Edge, Neoss AB, Gothenburg, Sweden) (Figure 1) using a one-stage protocol and loaded for at least one year. Data related to patient, type of treatment, implants, bone conditions, and outcomes at annual check-ups were extracted from a simple computerized system (MS Excel, Microsoft, Redmond, USA) used to keep track on consecutive implant treatments in the clinic. The study followed the World Medical Association Declaration of Helsinki and the directives given by the local ethical committee at the Feltre Hospital, Feltre, Italy.




Figure 1: Neoss ProActive Edge implants

A total of 36 patients (28 female, 8 male) treated with 56 implants and with a mean follow-up time of 2.7 ± 0.7 years were eligible for the study (Table 1). Nine implants had been placed in the mandible and 47 in the maxilla as support for 37 prosthetic devices: 16 single tooth replacements, 19 partial bridges, one full bridge and one overdenture (Table 2 and 3). The implants had been inserted according to a protocol using a 2.2 mm straight drill and tapered spiral drills (3.0 – 4.4 mm) and, if needed, a countersink bur. Insertion torque (IT)/time curves had been registered during placement with an Elcomed drilling unit (W&H Austria GmbH, Bürmoos, Austria). Resonance frequency analysis (RFA) measurements had been taken after implant placement using a PenguinRFA instrument (IDSAB, Gothenburg, Sweden). Impressions were made after surgery or after 6 to 12 weeks of healing for loading with a permanent prosthetic device.

Any notations in the patient charts of biologic (failure, marginal bone resorption, infection, pain etc) and/or technical (fracture, chipping) complications at follow-up appointments and annual check-ups were registered.

RESULTS

Clinical observations

Insertion of the Edge implant was found to be easy and gave a sensation of high stability irrespective of bone density. Most of the 3.5 mm implants could be placed after the use of one 2.2 mm spiral drill only (Figure 2). The remaining implants were placed after using two spiral drills (Figure 3).

Number of implants (failed)	Implant diameter				Total	
	3.5 mm	4.0 mm	4.5 mm	5.0 mm		
Implant length	9 mm	1	6	5 (1)	–	12
	11 mm	10	10	2	3	25
	13 mm	8	8	3	–	19
Total	19	24	10	3	56	

Table 1: Distribution of implants by implant length and diameter

Number of implants (failed)	Tooth position	Tooth position			Total
		Front	Premolar	Molar	
Jaw	Maxilla	6	24	17 (1)	47
	Mandible	2	4	3	9
Total		8	28	20	56

Table 2: Distribution of implants by jaw and tooth position

Number of constructions (failed)	Type of construction	Type of construction			Total
		Single tooth	Partial bridge	Full bridge / OD	
Jaw	Maxilla	12 (1)	17	1	30
	Mandible	4	2	1	7
Total		16	19	2	37

Table 3: Distribution of prosthetic constructions by jaw and type of construction

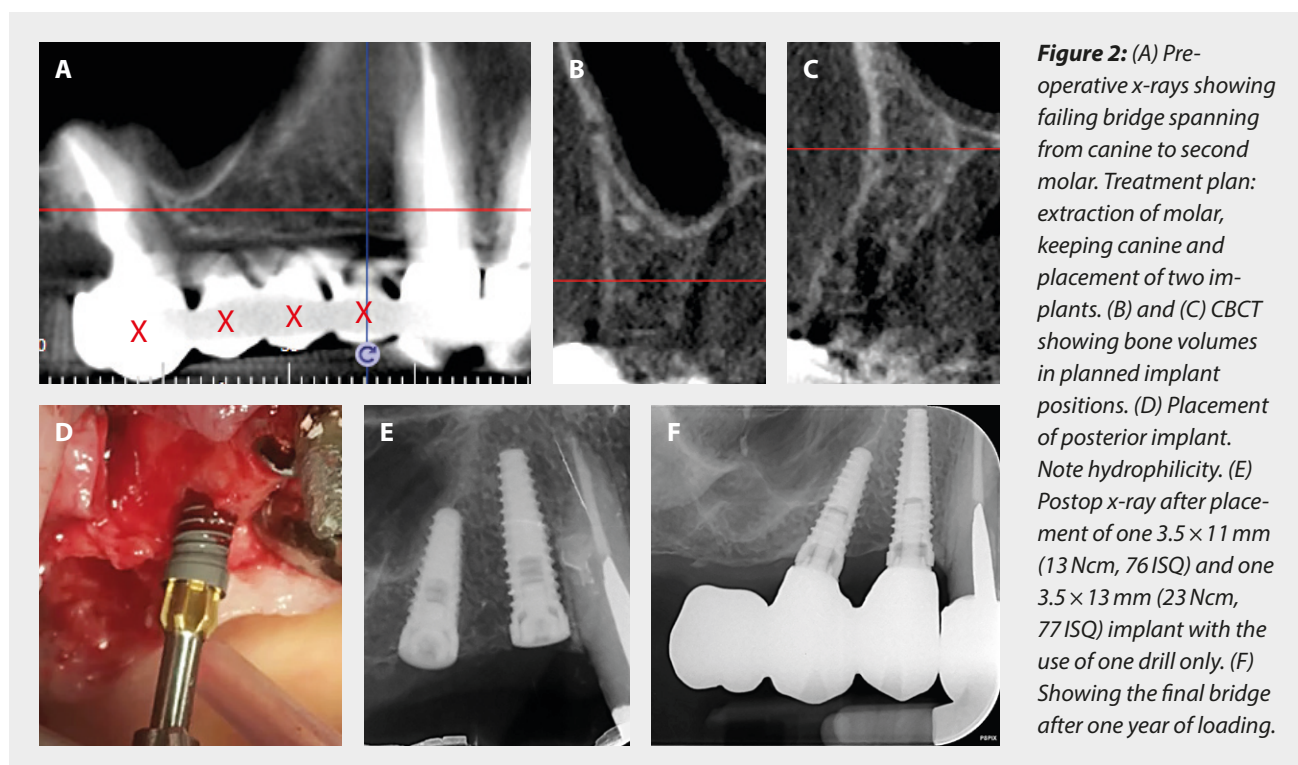


Figure 2: (A) Pre-operative x-rays showing failing bridge spanning from canine to second molar. Treatment plan: extraction of molar, keeping canine and placement of two implants. (B) and (C) CBCT showing bone volumes in planned implant positions. (D) Placement of posterior implant. Note hydrophilicity. (E) Postop x-ray after placement of one 3.5 × 11 mm (13 Ncm, 76 ISQ) and one 3.5 × 13 mm (23 Ncm, 77 ISQ) implant with the use of one drill only. (F) Showing the final bridge after one year of loading.

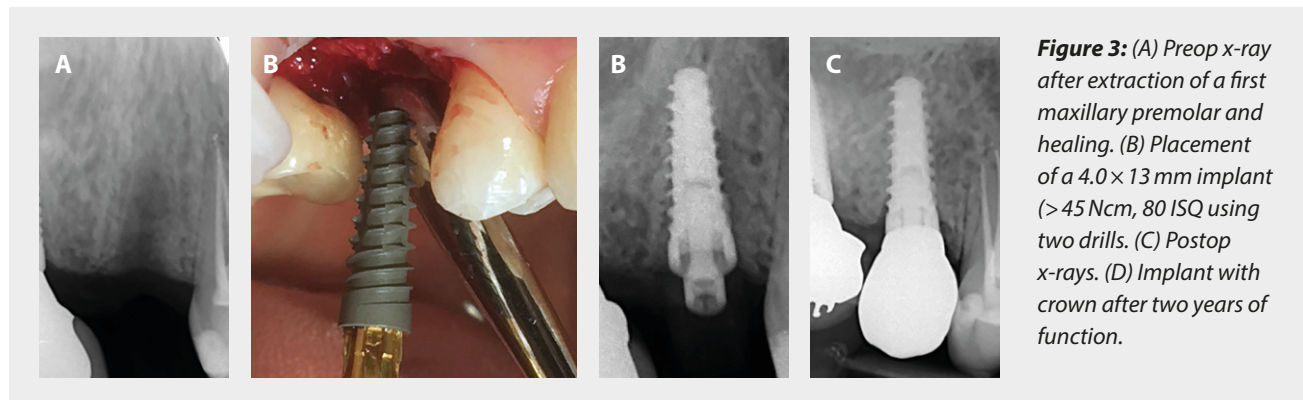


Figure 3: (A) Preop x-ray after extraction of a first maxillary premolar and healing. (B) Placement of a 4.0 x 13 mm implant (> 45 Ncm, 80 ISQ using two drills). (C) Postop x-rays. (D) Implant with crown after two years of function.

No countersink bur was used for 15 implants. When using a second tapered drill, almost half the length of the implant could be placed into the osteotomy, which together with the high thread pitch resulted in a swift placement (Figure 4). In most cases the implant could be inserted to the desired position in one go, i.e. with the collar flush with or slightly below the crest. Only a few implants needed to be finally seated with the manual wrench.

Time interval	Implants	Failed	Withdrawn / Not followed	CSR
Insert. – 1 year	56	1	0	98.2%
1 – 2 years	55	0	14	98.2%
2 – 3 years	41	0	30	98.2%
3 years	11	–	–	–

Table 4: Life table

One implant was lost during the one-year of follow-up giving a survival rate of 98.3% (Table 4). The implant (4.5 x 9 mm, first maxillary molar position) failed due to infection six weeks after placement.

There were no notations of rapid marginal bone loss and infections around any implant.

Implant stability

All implants achieved firm primary stability as assessed with IT (37.2 ± 17.7 Ncm, range 10 – 80 Ncm) and RFA (75.5 ± 5.2 ISQ, range 60 – 85 ISQ) measurements.

There was a weak correlation between IT/bone density and RFA values as also implants with low IT/low density generally showed high ISQ values (Figure 5).

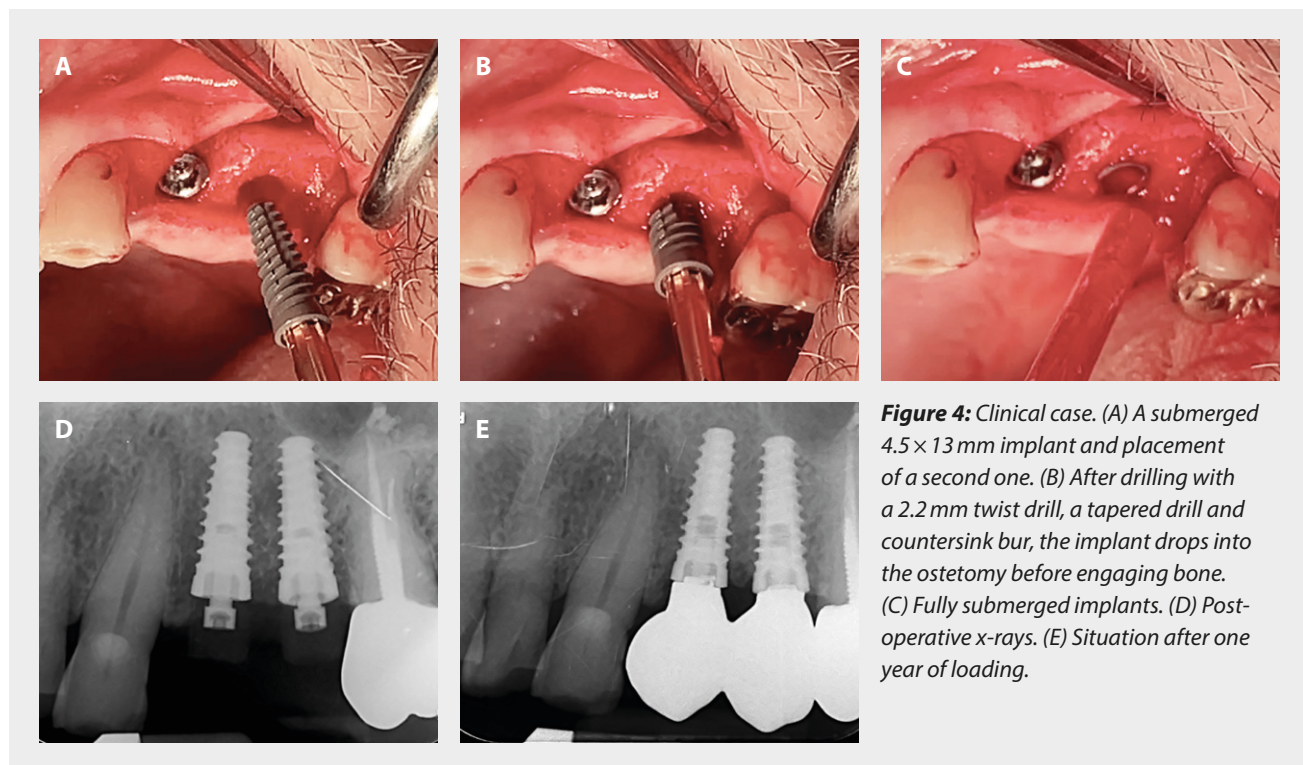
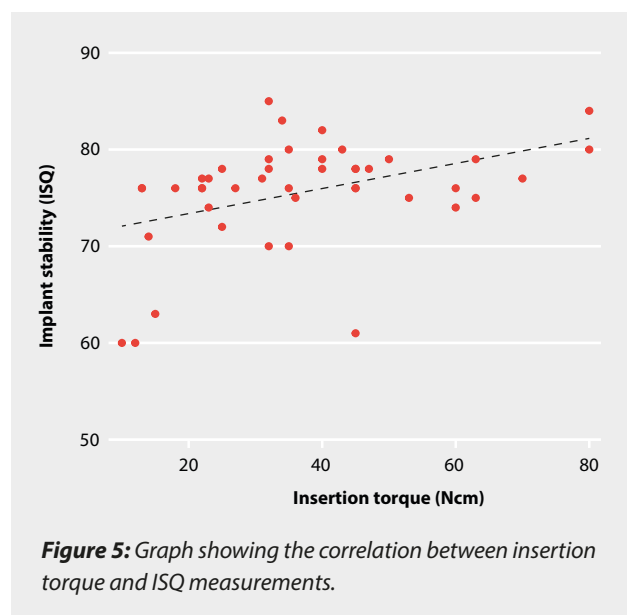


Figure 4: Clinical case. (A) A submerged 4.5 x 13 mm implant and placement of a second one. (B) After drilling with a 2.2 mm twist drill, a tapered drill and countersink bur, the implant drops into the osteotomy before engaging bone. (C) Fully submerged implants. (D) Post-operative x-rays. (E) Situation after one year of loading.

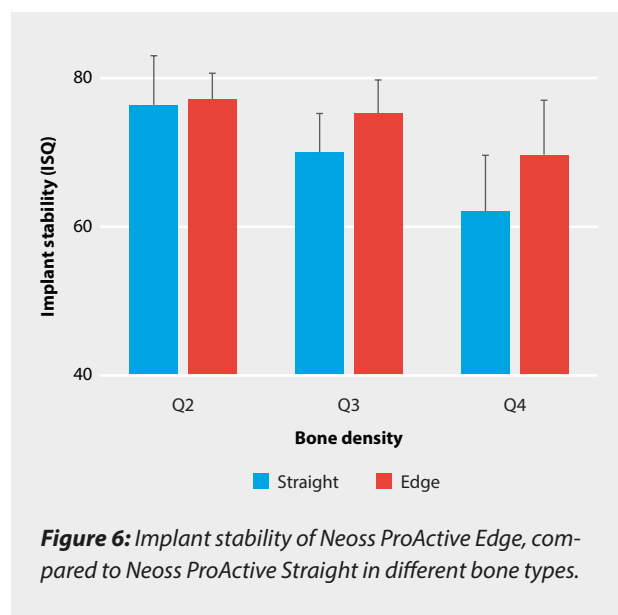


DISCUSSION

The present case series report showed that the novel Neoss Edge implant and simplified drilling protocol resulted in firm primary implant stability and good clinical outcomes after up to three years of loading. One implant (1.7%) was lost due to infection during healing. Although no marginal bone level measurements were included in the study, no cases with extensive marginal bone loss and/or infection were experienced. In a previous report on the first fifteen patients of the same group, we reported a mean marginal bone loss of 0.5 ± 0.6 mm after one year in function,¹ which is in line with studies on the other Neoss designs.⁵

A subjective feeling of high stability was obvious when placing the Edge implant, which was also confirmed by the RFA measurements. Interestingly, also implants with low IT and placed in soft bone generally showed firm stability. This is in line with the findings in vitro where the Edge implant showed high ISQ and low displacement values despite low insertion torque during the most challenging experimental conditions.² It was speculated that the wide collar of the implant was important as it enabled further clamping of the implant during insertion. A brief numerical comparison the present data with that from two previous clinical studies on Neoss Straight implants from our group,^{3,4} indicated firmer stability for the Edge implants in these situations (Figure 6). However, this needs to be statistically confirmed in comparative studies.

The present authors are following a primary stability-based loading protocol (Andersson et al) where implants showing ≥ 70 heal for six weeks, 65–70 ISQ for 8 weeks and if ≤ 65 for 12 weeks. In addition, it is our experience that immediate/early loading can be successfully applied if



≥ 70 ISQ. In the present study, all but three implants showed such a high stability and may have been suitable for rapid loading. However, further studies are needed, since all implants in the present study was restored after healing.

It is concluded that surgical placement of the novel Neoss Edge implant was found to be easy and gave a sensation of high stability irrespective of bone density as also confirmed with IT and ISQ measurements. One implant was lost early after surgery and there were no indications of adverse marginal bone loss.

REFERENCES

1. Turra M, Andersson P, Verrocchi D, Sennerby L. A retrospective case series report on a novel aggressively threaded and tapered implant. *Clin Oral Implants Res.* 2020;31(S20):257
2. Turra M, Petersson A, Sennerby L. Primary stability of three different aggressively threaded and tapered implants in low-density polyurethane. *Clin Oral Implants Res.* 2020;31(S20):60-61
3. Coppe M, Degaspero W, Andersson P, Verrocchi D, Sennerby L. 5-year results of Neoss dental implants restored at implant-Level. A retrospective follow-up study. *J Dent Maxillofac Res.* 2019;2:1-5
4. Sennerby L, Andersson P, Pagliani L, Giani C, Moretti G, Molinari M, Motroni A. Evaluation of a novel cone beam computed tomography scanner for bone density examinations in preoperative 3D reconstructions and correlation with primary implant stability. *Clin Implant Dent Relat Res.* 2015;17:844-853
5. Sahlin H. Implant survival, bone remodeling and implant stability of Neoss implants: a systematic review of the literature. *Letters Implant Dent.* 2017;1:15-20

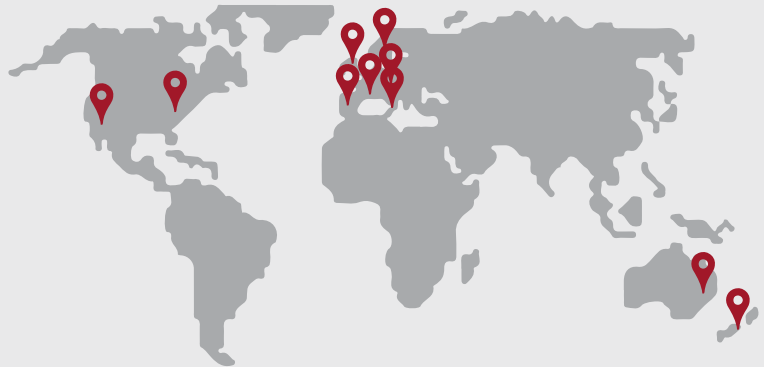Experience matters

Neoss ProActive® Edge Implant Ambassador Program

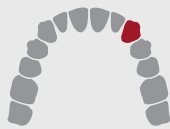More than 25 clinicians from all around the globe have tested the latest implant innovation from Neoss®.

Our Edge ambassadors provided valuable real-life user feedback based on > 50 patients representing a wide range of different clinical situations.

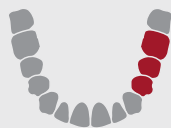In combination with ongoing study activities, this program ensures clinical experience and product confidence.



All bone types



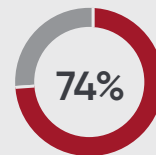
Single crowns



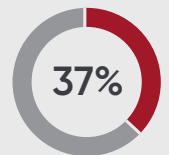
Partial bridges



Full arches



Maxilla



Extraction sites

Few drill steps

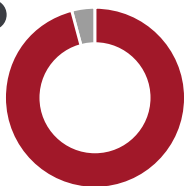


76%

of the implants were placed with 2 or fewer drills

94%

rated the drilling protocol as very easy or easy



Ease of use

Up to

10 min.

less chairtime per patient



96%

rated overall handling as excellent or good



Primary stability



94%

rated primary stability as better than expected or as expected

“

The Neoss Edge is a fabulous implant in soft bone or immediate sites. Precise placement with high primary stability.

– Dr. Scott Davis, Australia