

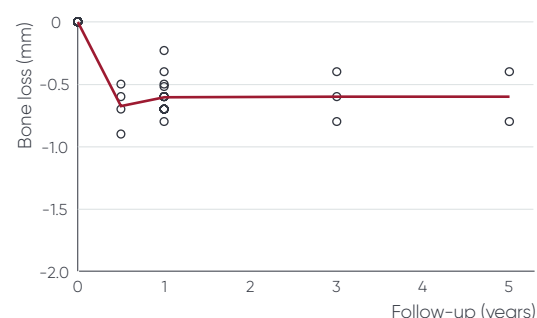
Proven performance

The clinical performance of the Neoss implant system is well documented, and the data speaks for itself. Eighteen independent clinical studies – with a follow-up time of 1 to 6 years, reporting on more than 2350 implants in more than 830 patients – show high implant survival, minimal bone resorption, and excellent primary and secondary stability in all types of bone.

High implant survival rates – The overall cumulative survival rate for ProActive implants is 97.8% after 1 year and 97.5% after 5 years.

Minimal bone resorption – The mean bone loss in all studies is 0.62 mm after 1 year, and 0.60 mm after 5 years. This indicates extremely stable marginal bone levels after a minimal bone resorption during the healing phase.

Excellent primary and secondary stability – The mean ISQ at time of implant insertion for all studies is 73.1 (range 68.1 – 76.7). The primary stability is generally maintained or even increased during the first year after implant placement.



Extremely stable bone levels over time. Compilation of all published studies on Neoss implants that report bone remodeling data (n=15). Each circle represent one study, the line represents the mean of all studies.

Study	Study type	Topic	Implant type	Follow-up time	Subgroups	No. of patients	No. of implants	Survival rate (CSR)	Bone loss (mm)
Zumstein 2012 ¹ Zumstein 2008 ²	Retrospective controlled	GBR vs. non-GBR	Straight	4-5 years		50	183	95.0%	0.4
					Non-GBR	-	57	98.2%	-
					GBR	-	126	93.5%	-
Sennerby 2016 ³ Degasperis 2012 ⁴	Retrospective case series	Long-term follow-up on ProActive	Straight	60 months		49	102	98.0%	0.8
Sennerby 2016 ⁵	Retrospective case series	Immediate placement, early loading, full-arch	Straight, Tapered	1-6 years		43	258	96.5%	-
Andersson 2015 ⁶	Retrospective controlled	Immediate placement, early loading, full-arch	Straight	1-6 years		50	284	93.7%	0.8
					Bimodal	-	116	89.7%	-
					ProActive	-	168	96.4%	-
Acham 2017 ⁷	Randomized controlled trial	Overdenture on Locator abutments	Not reported	3 years		20	80	100%	-
Vanden Bogaerde 2016 ⁸	Randomized controlled trial	Early implant stability	Straight	3 years		11	22	95.5%	0.5
Dahlin 2013 ⁹	Prospective case series	Multi-center	Straight	1 year		177	590	97.8%	0.6
Becker 2013 ¹⁰	Prospective case series	One-stage, delayed load	Straight	14 months		76	100	93%	0.6
Sennerby 2012 ¹¹	Prospective case series	Two-stage surgery	Straight	1 year		90	218	98.6%	0.6
Zwaan 2016 ¹²	Retrospective case series	Tapered implants	Tapered	1 year		97	163	96.9%	0.5

Table continues on next page

Study	Study type	Topic	Implant type	Follow-up time	Subgroups	No. of patients	No. of implants	Survival rate (CSR)	Bone loss (mm)
Aktas 2015 ¹³ Aktas 2014 ¹⁴	Retrospective case series	Bar-retained overdenture on four implants	Not reported	3 years		10	52	100%	-
Vanden Bogaerde 2010 ¹⁵	Prospective case series	Immediate loading	Straight	18 months		21	69	98.5%	0.7
Zumstein 2016 ¹⁶	Retrospective controlled	GBR vs. non-GBR	Straight	1 year	<i>Non-GBR</i> <i>GBR</i>	50 - -	159 67 92	98.7% 98.5% 98.9%	0.7 - -
Di Lallo 2014 ¹⁷	Prospective controlled	Sinus lift	Straight	1 year		25	38	100%	-
Alsabeeha 2011 ¹⁸	Randomized controlled trial	Overdenture on single implant	Straight	1 year		12	12	100%	0.2
Wiesner 2010 ¹⁹	Randomized controlled trial	Connective tissue grafts	Straight	1 year		10	20	100%	0.7
Andersson 2008 ²⁰	Retrospective case series	Two-stage surgery	Straight	1 year		44	102	98.1%	0.7
Volpe 2013 ²¹	Retrospective case series	Sinus lift, osteotome method	Straight	16 months		20	29	100%	0.7
Pagliani 2012 ²²	Prospective case series	Bone grafting	Straight	1 year		19	34	97.1%	0.5

References

- Zumstein T, Billstrom C, Sennerby L. A 4- to 5-year retrospective clinical and radiographic study of Neoss implants placed with or without GBR procedures. *Clin Implant Dent Relat Res.* 2012;14:480-90.
- Zumstein T, Billstrom C. A Retrospective Follow-up of 50 consecutive patients treated with Neoss Implants with or without an Adjunctive GBR-Procedure. *Appl Osseointegration Res.* 2008;6:31-5.
- Sennerby L, Coppe M, Andersson P, Verrocchi D. A 5-year clinical and radiographic follow-up of hydrophilic implants restored at implant level. *Clin Oral Implants Res.* 2016;27:342 (Poster PPR-444).
- Degasperi W, Andersson P, Verrocchi D, Sennerby L. One-year clinical and radiographic results with a novel hydrophilic titanium dental implant. *Clin Implant Dent Relat Res.* 2014;16:511-9.
- Sennerby L, Turra M, Andersson P, Verrocchi D. Total extraction and simultaneous implant placement for early loading of a full maxillary fixed provisional bridge within 3 days. A 1 to 6 year follow-up study. *Clin Oral Implants Res.* 2016;27:522 (Poster PIM-624).
- Andersson P, Degasperi W, Verrocchi D, Sennerby L. A Retrospective Study on Immediate Placement of Neoss Implants with Early Loading of Full-Arch Bridges. *Clin Implant Dent Relat Res.* 2015;17:646-57.
- Acham S, Rugani P, Truschnegg A, Wildburger A, Wegscheider WA, Jakse N. Immediate loading of four interforaminal implants supporting a locator-retained mandibular overdenture in the elderly. Results of a 3-year randomized, controlled, prospective clinical study. *Clin Implant Dent Relat Res.* e2017.
- Vanden Bogaerde L, Sennerby L. A Randomized Case-Series Study Comparing the Stability of Implant with Two Different Surfaces Placed in Fresh Extraction Sockets and Immediately Loaded. *Int J Dent.* 2016;2016:8424931.
- Dahlin C, Widmark G, Bergkvist G, Furst B, Widbom T, Kashani H. One-year results of a clinical and radiological prospective multicenter study on NEOSS(R) dental implants. *Clin Implant Dent Relat Res.* 2013;15:303-8.
- Becker W, Becker BE, Hujuel P, Abu Ras Z, Goldstein M, Smidt A. Prospective clinical trial evaluating a new implant system for implant survival, implant stability and radiographic bone changes. *Clin Implant Dent Relat Res.* 2013;15:15-21.
- Sennerby L, Andersson P, Verrocchi D, Viinamäki R. One-year outcomes of Neoss bimodal implants. A prospective clinical, radiographic, and RFA study. *Clin Implant Dent Relat Res.* 2012;14:313-20.
- Zwaan J, Vanden Bogaerde L, Sahlin H, Sennerby L. A One-year Follow-up Study of a Tapered Hydrophilic Implant Design Using Various Placement Protocols in the Maxilla. *Open Dent J.* 2016;10:680-691.
- Aktas G, Guncu M, Tozum TF. Three-year outcome of retrospective study on four implant retained overdentures with bar attachment. *Clin Oral Implants Res.* 2015;26:324 (Poster #484).
- Aktas G, Guncu M, Tozum TF. Clinical evaluation of four implant retained overdentures with bar attachment: 2 year retrospective study. *Clin Oral Implants Res.* 2014;25:604 (Poster #581).
- Bogaerde LV, Pedretti G, Sennerby L, Meredith N. Immediate/Early function of Neoss implants placed in maxillas and posterior mandibles: an 18-month prospective case series study. *Clin Implant Dent Relat Res.* 2010;12 Suppl 1:e83-94.
- Zumstein T, Sennerby L. A 1-Year Clinical and Radiographic Study on Hydrophilic Dental Implants Placed with and without Bone Augmentation Procedures. *Clin Implant Dent Relat Res.* 2016;18:498-506.
- Di Lallo S, Ricci L, Orecchioni S, Piattelli A, Iezzi G, Perrotti V. Resonance frequency analysis assessment of implants placed with a simultaneous or a delayed approach in grafted and nongrafted sinus sites: a 12-month clinical study. *Clin Implant Dent Relat Res.* 2014;16:394-400.
- Alsabeeha NH, Payne AG, De Silva RK, Thomson WM. Mandibular single-implant overdentures: preliminary results of a randomised-control trial on early loading with different implant diameters and attachment systems. *Clin Oral Implants Res.* 2011;22:330-7.
- Wiesner G, Esposito M, Worthington H, Schlee M. Connective tissue grafts for thickening peri-implant tissues at implant placement. One-year results from an explanatory split-mouth randomised controlled clinical trial. *Eur J Oral Implantol.* 2010;3:27-35.
- Andersson P, Verrocchi D, Viinamäki R, Sennerby L. A One-Year Clinical, Radiographic and RFA Study of Neoss Implants Used in Two-Stage Procedures. *Appl Osseointegration Res.* 2008;6:23-6.
- Volpe S, Lanza M, Verrocchi D, Sennerby L. Clinical outcomes of an osteotome technique and simultaneous placement of Neoss implants in the posterior maxilla. *Clin Implant Dent Relat Res.* 2013;15:22-8.
- Pagliani L, Andersson P, Lanza M, Nappo A, Verrocchi D, Volpe S, Sennerby L. A collagenated porcine bone substitute for augmentation at Neoss implant sites: a prospective 1-year multicenter case series study with histology. *Clin Implant Dent Relat Res.* 2012;14:746-58.