

Neoss ScanPeg – simplified intra-oral scanning

A 4.0×11 mm Neoss ProActive® Tapered implant was placed in the lower first molar position following 3D radiological examination. A minimal flap was raised to split the small amount of keratinized soft tissue. Excellent primary stability was obtained, insertion torque >50 Ncm and 76 ISQ.

Dr. Jakob Zwaan, Italy

Patient: 60 year old woman. Non-smoker in good general health.

Clinical situation: Missing lower first molar. Part of a complex case with multiple reconstructions in both jaws.

Treatment plan: Placement of Esthetic Healing Abutment at time of implant placement. Digital impression using the Neoss ScanPeg. CAD/CAM CoCr single crown with angulated screw hole.

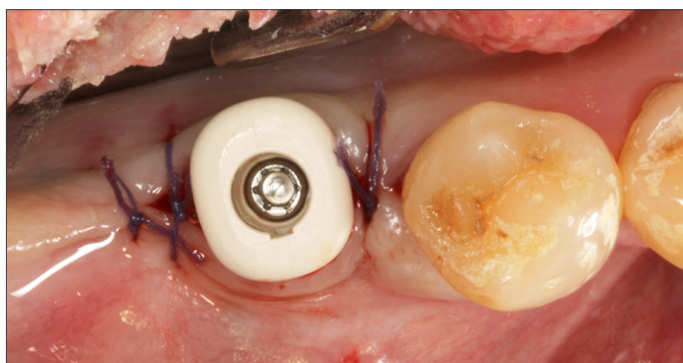


Figure 1.

An Esthetic Healing Abutment Pre-molar was placed and the soft tissue closed with single sutures (Figure 1).

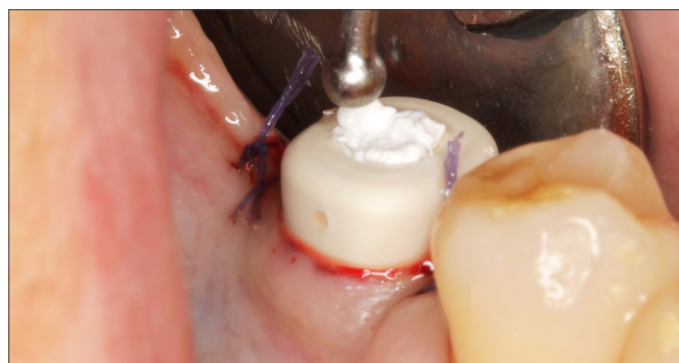

Figure 2.

Note the buccal orientation of the groove, which functions as a direction feature, to ensure proper anatomical transgingival shape. The screw channel was filled with PTFE material (Figure 2).

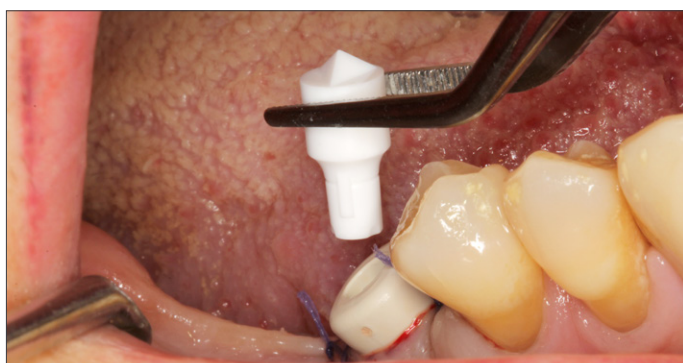

Figure 3.

At time of scanning, the PTFE material was removed, the push-in ScanPeg was seated inside the Healing Abutment (Figure 3 & 4), and an intra-oral scan was taken.

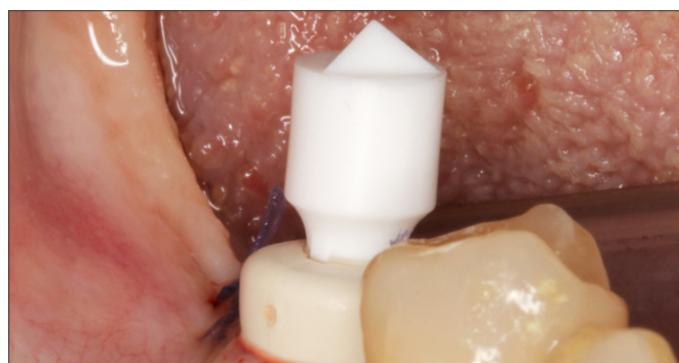

Figure 4.

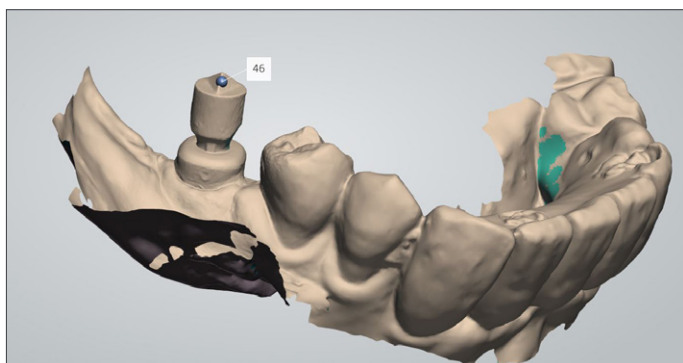


Figure 5.

The assembly allows the digital impression of the implant position and soft tissue (Figure 5) to be taken without unscrewing the abutment, thereby leaving the healing of the soft tissue completely undisturbed.

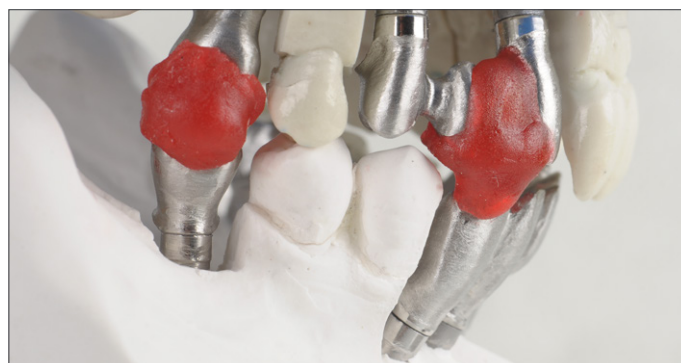

Figure 6.

Since there was no need for a temporary crown for esthetic reasons, and the soft tissue was conditioned by the healing abutment, it was decided to immediately produce the definitive restoration. A CAD crown was designed by the laboratory with a minor correction of axis (12°). A library of preset transgingival shapes in the CAD library that matched the shape of the healing abutment simplified the design work. A Cobalt Chromium restoration was milled (Arc Solutions, Helsingborg, Sweden). The milled abutment was mounted in the stone model and occlusion was tested before layering the framework with porcelain (Figure 6).

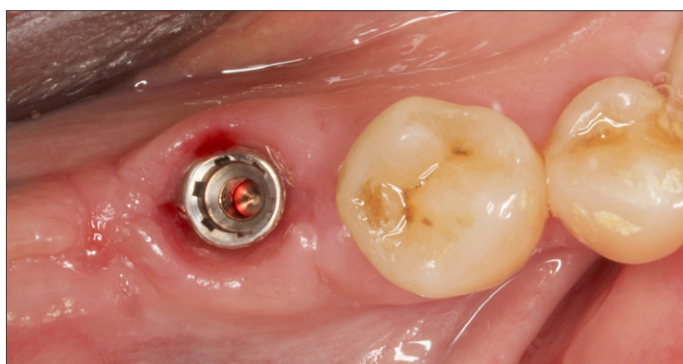


Figure 7.

At time of placement of the final restoration, the Esthetic Healing Abutment was removed, revealing a mucosa around the implant anatomically shaped by the Healing Abutment (Figure 7).

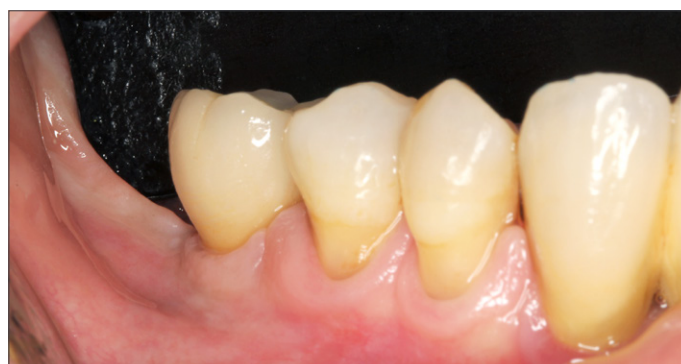

Figure 8.

Final restoration with matching transgingival shape in place (Figure 8).